

# CAT

N° 62 | SPRING 2015

# news





**CATnews** is the newsletter of the Cat Specialist Group, a component of the Species Survival Commission SSC of the International Union for Conservation of Nature (IUCN). It is published twice a year, and is available to members and the Friends of the Cat Group.

**For joining the Friends of the Cat Group please contact Christine Breitenmoser at [ch.breitenmoser@kora.ch](mailto:ch.breitenmoser@kora.ch)**

Original contributions and short notes about wild cats are welcome

**Send contributions and observations to [ch.breitenmoser@kora.ch](mailto:ch.breitenmoser@kora.ch).**

**Guidelines** for authors are available at [www.catsg.org/catnews](http://www.catsg.org/catnews)

**CATnews** is produced with financial assistance from the Friends of the Cat Group.

Design: barbara surber, werk'sdesign gmbh  
Layout: Christine Breitenmoser  
Print: Stämpfli Publikationen AG, Bern, Switzerland

**ISSN 1027-2992** © IUCN/SSC Cat Specialist Group

The designation of the geographical entities in this publication, and the representation of the material, do not imply the expression of any opinion whatsoever on the part of the IUCN concerning the legal status of any country, territory, or area, or its authorities, or concerning the delimitation of its frontiers or boundaries.

**Editors:** Christine & Urs Breitenmoser  
Co-chairs IUCN/SSC  
Cat Specialist Group  
KORA, Thunstrasse 31, 3074 Muri,  
Switzerland  
Tel ++41(31) 951 90 20  
Fax ++41(31) 951 90 40  
<[u.breitenmoser@vetsuisse.unibe.ch](mailto:u.breitenmoser@vetsuisse.unibe.ch)>  
<[ch.breitenmoser@kora.ch](mailto:ch.breitenmoser@kora.ch)>

**Associate Editors:** Keith Richmond  
Brian Bertram  
Sultana Bashir  
Javier Pereira

**Cover Photo:** Fishing cat  
Photo Devan Sewell

MOHAMMAD S. FARHADINIA<sup>1,2\*</sup>, IMAN MEMARIAN<sup>2</sup>, ALIREZA SHAHRDARI<sup>2</sup>, MOHAMMAD TAGHDISI<sup>3</sup>, BEHROUZ JAFARI<sup>3</sup>, MOHAMMAD MOLAZEM<sup>4</sup>, FATEMEH MOGHANI<sup>4</sup> AND DAVID W. MACDONALD<sup>1</sup>

## Capturing an old problem Persian leopard close to the Iran-Turkmenistan border

**A Persian leopard *Panthera pardus saxicolor* was habitually attacking domestic animals near the village of Tazeh Ghaleh in northeastern Iran. Initially, during summer 2014, it killed mainly small livestock, before switching predominantly to herd dogs. Moreover, the leopard attacked three people. In October 2014, the villagers reported the situation to the local authorities, seeking a solution. Therefore, the Iranian Department of Environment considered live-capturing and translocation of the animal to a nearby reserve. Foot-snares were set at three locations within the village's territory. The leopard was captured on the third night, the snare had been set close to the carcass of a dog it had killed recently. The leopard was safely anaesthetised, biometrical measurements and samples taken. Its dentition indicated that the animal, a male, was old, estimated at more than 10 years. Biochemical examination of the blood sample revealed severe hepatic and renal problems. Although contingency plans for translocation had been made, as events unfolded it was concluded that the animal was not suitable for release into the wild, and should be held in captivity under intensive veterinary care. Therefore, the leopard was translocated to the Wildlife Rehabilitation Centre in Tehran. Carefully documented individual cases, such as this, illustrate vividly the practicalities of tackling human-carnivore conflict, and the need to respond adaptively as each situation unfolds.**

Northeastern Iran harbours part of the remaining population of the endangered Persian leopard, spanning Afghanistan through Iran to the Caucasus. Conflict with human communities is one of the main causes of population

decline in Iran, and sometimes culminates in retaliatory killing of the predator. Conflict between carnivores and the people that they live alongside has informed generalisations about the nature of the problems and the ca-

tegories of solution. Considering felids, and especially big ones, Macdonald et al (2010) applied some of these generalisations. They are compiled by the accumulating experience of diverse approaches to human-wildlife conflict and are brought down to earth, and made vivid, by individual case histories. Here we present such an informative case history for a Persian leopard.

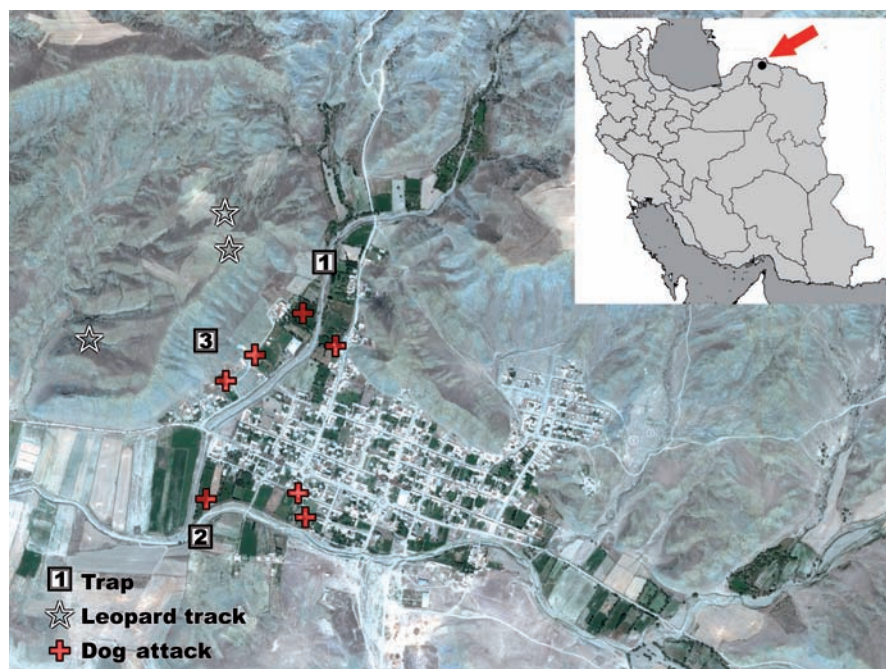
The Iranian Department of the Environment DoE runs a compensation program in order to pay for livestock lost to predators. However, DoE faces challenges on many fronts, including inadequate funding, insufficient training and lack of cooperation between key stakeholders. Furthermore, awareness raising initiatives or non-lethal conflict resolutions have not quelled the conflict. As a result, nationwide, in 2013 alone, 63 % of the leopards killed by people succumbed as a result of conflict (the remainder died in road-traffic collisions or by poachers; Memarian et al. 2014).

For more than three decades, translocation of problem carnivores has been a standard method to remove them from areas of conflict (Linnell et al. 1997). However, to the best of our knowledge, it has been rarely applied to west Asian carnivores, although Z. Salahshour (pers. comm.) has told us of one case of a female leopard translocated from a village near Tandoureh National Park after killing dogs in 2011. While translocating problem animals has sometimes been successful in the case of some big cats, such as Amur tiger *P. tigris altaica* (Goodrich & Miquelle 2005), doubt has been cast over its effectiveness specifically with regard to leopards (Linnell et al. 2007, Athreya et al. 2011, Weise et al. 2015). In this context, we report here the case history of an attempt to resolve severe conflict between local people and an adult Persian leopard through live-capture in the borderland of Iran-Turkmenistan.

### Case report

Since August 2014, an adult Persian leopard had been attacking domestic animals near the village of Tazeh Ghaleh in northeastern Iran (Fig.1). Located just a few kilometres from the Turkmenistan border, the village is surrounded by rolling terrain (Fig. 2) with juniper trees sparsely distributed on slopes within the Kopet Dagh region, a global high biodiversity hotspot.

Between July and the end of September 2014, at least 5 sheep and goat were killed; during this season most herds were guarded by shepherds and their dogs overnight in the



**Fig. 1.** Location of dog attacks in Tazeh Ghaleh village in northeastern Iran. Almost half of the attacks on the dogs occurred outside the village area. The leopard was captured at trap 3.

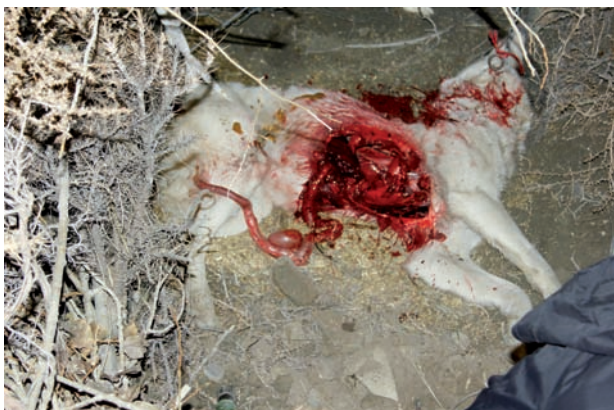

**Fig. 2.** View of Tazeh Ghaleh village, photographed from a ridge where the leopard was frequently seen (Photo M. Farhadinia).

pastures. After October, most herds concentrated their daily grazing around the village and livestock were contained in corrals, within the village, overnight. During an attack on one herd, dogs chased the leopard, which killed one of them. The leopard then attacked three people who tried to approach it on the dead dog. As a result, the villagers were fearful and stayed within their homes overnight. Following snowfall in November 2014, the leopard's tracks were seen along the main routes through the village and its scrapes were found on the roof of a house.

In October 2014, the villagers reported the situation to the local authorities, seeking a solution. Thus, experts in Iran's DoE tried a variety of methods to deter the leopard from the village, and advised the villagers on husbandry and personal safety. Furthermore, they tried to set fires around the village, igniting gunpowder at high risk places, and fired shots into the air in attempts to frighten the leopard. The leopard persisted in killing dogs.

Between mid-August and mid-December 2014, the leopard killed 15 herd dogs (Fig.3),



**Fig. 3.** The herd dog killed by the leopard and used as bait for the trap (Photo: A. R. Shahrđari).

which is about one animal per week, and continued sporadically to kill livestock. The area's natural prey, i.e. urial sheep and wild boar are depleted.

The DoE was under increasing pressure from local and regional authorities to resolve the problem or to shoot the animal. Thus, in mid-December 2014 the authorities reached the conclusion that the leopard, which was then thought by the DoE team to be a sub-adult male, should be translocated. Following successful precedent in northeastern Iran, the DoE therefore requested the project team (MSF and IM) to live-capture the leopard and translocate it to the nearby Goloul-Sarani Protected Area. This reserve has been protected since 1971 and is populated by several hundred urial sheep and was thought to be devoid of resident leopards (n=3 persons).

Subsequently, camera trap video suggested that the leopard was actually an old male with dental problems. Our team deployed foot-snares which had previously been used successfully to catch leopards in Iran. Baited with the carcass of a dog recently killed by the

leopard, traps were set at three locations, all within the curtilage of the village (Fig.1). Each trap site comprised two sets of snares (Frank et al. 2003), monitored remotely by a Telonics TBT-500 trap site transmitter (Telonics Inc., Mesa, USA), and monitored at 30-60 minutes intervals. People were asked to avoid the trap sites, and to keep their dogs away.

On the third night (20 December), a trap was activated at 17:00 h; the capture team arrived within 20 minutes. The leopard was snared by the left forepaw. The animal appeared heavy and its weight was estimated 75 kg. Persian leopards in Iran have been recorded at weights up to 90 kg (Farhadinia et al. 2014) and anaesthesia was safely achieved using a combination of Ketamine 10% (Alfasan, Nederland BV) 3 mg/kg and Medetomidine HCL 20 mg/ml (Kyron Laboratories (Pety) Ltd., Johannesburg, South Africa) 30 µg/kg administered IM in the same 1.5 ml dart by Daninject darting gun. The darting site was triceps brachii (Fig.4, Supporting Online Material SOM Table T1).

Capture-related injuries were investigated, and amounted to only minor cuts and abrasions to the feet. Biometrical measurements (SOM F1 & SOM T2) and biological samples were taken. Mucous membrane was slightly pale and the pelage condition was poor. Its teeth were yellow with worn, broken canines and incisors. Most of the lower and upper incisors were missing. Mandibular and maxillary canine teeth had developed fractures with exposure of the pulp cavity. A discoloured tooth and an extra-oral draining fistula were also found, perhaps indicative of endodontic disease. The field team concluded that the male was more than 10 years old, according to age determination criteria developed by Stander (1997; Fig. 4). Accordingly, plans for radio-collaring and translocation were abandoned and, following reversal using Atipamazole X 5 medetomidine dosage, injected in triceps, the leopard was transported on a 4WD vehicle (around 800 km) to the Wildlife Rehabilitation Centre in Tehran. A practical difficulty was, despite our requests to the border guards to stop people from approaching the capture scene, loading the leopard for transport was hampered because onlookers sought to see it.

Haematology revealed no abnormality in the complete blood count (CBC), but biochemical examination of the serum sample indicated functional renal problems (SOM T3). However, no change in the echogenicity or structure of both kidneys was visible under ultrasonographic examination. IVP (intravenous pyelogram) revealed that the collecting system inside the kidneys was normal. Once at the rehabilitation centre in Tehran, the leopard was treated with Enalapril 5mg (Enalapril 5-ABIDI, Tehran, Iran) 0.25 mg/kg PO once daily and IRC-VET (Pharmadiet VETERINARIA, Spain) 2 tablets PO once daily. After around

five weeks, the Wildlife Rehabilitation Centre announced that the leopards died due to renal infection.

### Conclusion

Amongst the interventions considered to resolve conflict between people and leopards, live-capture of problem individuals is generally a last resort (Weise et al. 2015). When live-capture occurs, the expectation is generally that it is part of translocation, although the generality appears to be that this is often ineffective; clearly, the focus should be preventing and mitigating conflict, most importantly, by improving livestock-husbandry practices (Weilenmann et al. 2010, Athreya et al. 2011, Weise et al. 2015).

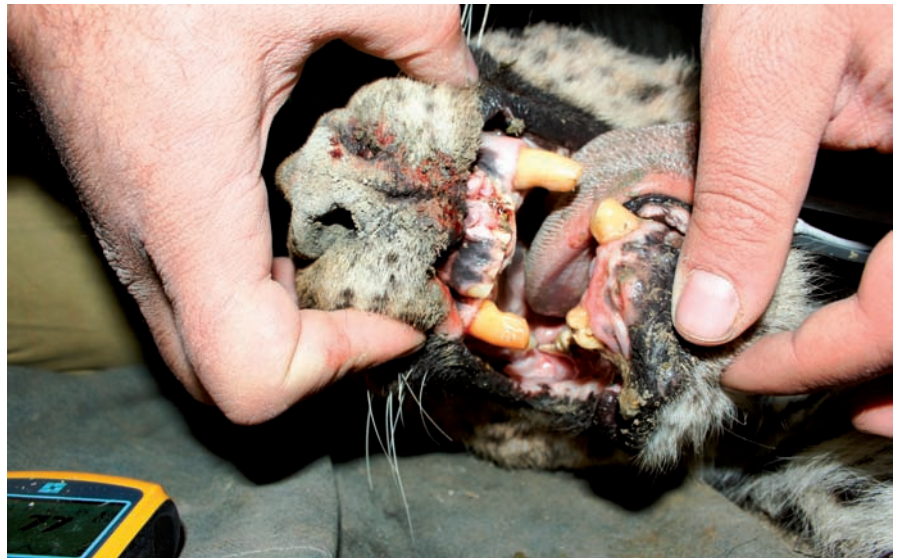In this case, however, live capture was considered to be the only alternative to shooting the leopard, and while translocation might have been feasible, the age and poor health of the leopard convinced the field team that the correct action was to retain it under veterinary care.

The first author (MSF) has investigated more than 75 leopard skulls from Iran, including from the northeast. However, no individual in this sample has shown signs of greater age than this individual. In 2008, two old male leopards, with poor dentition, were captured from southern Turkmenistan to found a breeding program for Persian leopard in Sochi, Russia. Insofar as advanced age is an indicator of a stable population, the capture of this elderly leopard raises the hope that a leopard population exists on the Iran-Turkmenistan border. Local hunters and game guards report that the Turkmen side of the border is well-populated by prey such as arial sheep.

Our main purpose in documenting this case history is to add to store of such episodes that make vivid the realities of living with problematic carnivores and of intervening in an attempt to mitigate them. In addition, considering that the episode described here may recur, a practical lesson to be learnt is that it would be prudent to establish a response team with relevant expertise and equipment, to be at the ready. However, there is no doubt that the long-term survival of the Persian leopards depends on limiting conflict, and a plan to foster their coexistence with local communities.

### Acknowledgments

We are indebted to the Conservation of Asiatic Cheetah Project and Panthera for sharing trapping



**Fig. 4.** The leopard's teeth were yellow with well-worn and broken canines and incisors which revealed that it is an old adult male leopard, estimated more than 10 years-old (Photo M. Farhadinia).

equipment. Luke Hunter made helpful comments on an earlier draft.

### References

- Athreya V., Odden M., Linnell J. D. & Karanth K. U. 2011. Translocation as a tool for mitigating conflict with leopards in human dominated landscapes of India. *Conservation Biology*, 25, 133-141.
- Farhadinia M. S., Kaboli M., Karami M. & Farahmand H. 2014. Patterns of sexual dimorphism in the Persian leopard (*Panthera pardus saxicolor*) and implications for sex differentiation. *Zoology in the Middle East* 60, 195-207.
- Frank L., Simpson D. & Woodroffe R. 2003. Foot snares; an effective method for capturing African lions. *Wildlife Society Bulletin* 31, 309-314.
- Goodrich J.M. & Miquelle D.G. 2005. Translocation of problem Amur tigers *Panthera tigris altaica* to alleviate tiger-human conflicts. *Oryx* 39(4): 454-457.
- Linnell J. D. C., Aanes R., Swenson J. E., Odden J. & Smith M. E. 1997. Translocation of carnivores as a method for managing problem animals: a review. *Biodiversity and Conservation* 6, 1245-1257.
- Macdonald D. W., Loveridge A. J., & Rabinowitz A. 2010. Felid futures: crossing disciplines, borders, and generations. *In* The Biology and Conservation of Wild Felids. Macdonald D. W. & Loveridge A. J. (Eds). Oxford University Press, Oxford, pp. 599-649.
- Memarian I., Dehghan M. M., Molazem M., Pedram M. S., Rostami A., Vali Y., Farzad S., Zehtabvar O., Shahrhiri A.R., Hamidi A. H. K. & Abdolmalekian N. 2014. Extinction sha-
- dows over Persian leopards (*Panthera pardus saxicolor*) due to human animal conflict. *Proceeding of International Conference on Diseases of Zoo and Wild Animals 2014*, Warsaw, Poland, pp. 2-9.
- Stander, P. E. 1997. Field age determination of leopards by tooth wear. *African Journal of Ecology* 35, 156-161.
- Weilenmann M., Gusset M., Mills D. R., Gabanapelo T. & Schiess-Meier M. 2010. Is translocation of stock-raiding leopards into a protected area with resident conspecifics an effective management tool? *Wildlife Research* 37, 702-707.
- Weise F., Lemeris J., Stratford K.J., van Vuuren R.J., Munro S.J., Crawford S.J., Marker L.L., Stein A.B. 2015. A home away from home: insights from successful leopard (*Panthera pardus*) translocations. *Biodiversity and Conservation* 24, 1755-1774.

Supporting Online Material SOM Figures F1-F2 and Tables T1-T3 is available at [www.catsg.org](http://www.catsg.org)

- 1 Wildlife Conservation Research Unit, Department of Zoology, University of Oxford, The Recanati-Kaplan Centre, Tubney, Abingdon OX13 5QL, UK \*[mohammad.farhadinia@zoo.ox.ac.uk](mailto:mohammad.farhadinia@zoo.ox.ac.uk)
- 2 Iranian Cheetah Society (ICS), P.O.Box 14155-8549, Tehran, Iran
- 3 Tehran Zoo and Pardisan Rehabilitation Centre, 1484613111 Tehran, Iran
- 4 North Khorasan Provincial Bureau, Department of Environment, Bojnourd, Iran
- 5 University of Tehran, Faculty of Veterinary Medicine, Dept. of Radiology and Surgery, 141556453 Tehran, Iran